



CITYU VETERINARY DIAGNOSTIC LABORATORY
城大動物醫療檢驗有限公司

CITY U VETERINARY DIAGNOSTIC LABORATORY

WELCOME MESSAGE FROM THE DIRECTOR

Welcome to the inaugural edition of the CityU Veterinary Diagnostic Laboratory newsletter. Our mission here at CityU VDL is to provide an accurate and timely diagnostic service to veterinarians of Hong Kong and the surrounding region, while assisting with the teaching programme of the College of Veterinary Medicine and Life Sciences and supporting research and disease investigations.

Our new laboratory is located on the campus at City University of Hong Kong and contains all the latest equipment operated by highly trained and experienced staff.

Cytology, post mortem and histopathology services are provided by specialist pathologists Drs Allan Kessell, Jeanine Sandy and myself on-site here in Hong Kong. Our pathologists welcome your contact by telephone or email to discuss sample submissions or the results of your cases.

Microbiology and molecular testing is now available, led by our microbiology veterinarian Dr Vidya Bhardwaj and molecular scientist Dr Christina To.

I am excited about the opportunities to investigate and diagnose diseases in Hong Kong and look forward to working with veterinary businesses in Hong Kong and the region.

- Dr. Fraser Hill, Anatomic Pathologist, Director of CityU VDL

IN THIS ISSUE

1 WELCOME MESSAGE FROM
THE DIRECTOR

2 EASTER HOLIDAY OPENING
HOURS

3 A WARM WELCOME TO OUR
NEW PATHOLOGIST

4 OUR VETERINARY
PATHOLOGIST

5 CITYU VDL UPDATES: NEW
TESTS

6 WHAT IS YOUR
DIFFERENTIAL DIAGNOSIS

7 CASE OF THE MONTH

A WARM WELCOME TO OUR NEW PATHOLOGIST

CityU VDL is excited to welcome our new anatomic pathologist, Dr. Jeanine Sandy, to our growing team of pathologists.



Dr. Jeanine Sandy

BVSc, MANZCVSc, PhD, Dip ACVP (Anatomic Pathology)

Dr Jeanine Sandy has worked as a small animal clinician in various practices in Australia after graduating from University of Queensland in 1991. In 1999, she completed a PhD in Feline AIDS/Virology. Starting 2000, she worked as a lecturer/senior lecturer at Melbourne University, trained by

the late Prof Jubb, as an anatomic pathologist. In 2010, she obtained her American Board qualifications as an anatomic pathologist whilst working as a clinical instructor at North Carolina State University. Before becoming part of the team at CityU VDL, she worked at QML Vetnostics in Brisbane, Australia as a general pathologist. Dr. Sandy's special areas of interests include liver, bone and skin pathology as well as laboratory animal pathology.

Dr. Sandy is based in our laboratory located within City University of Hong Kong and can be contacted via email at j.sandy@cityu.edu.hk

OUR VETERINARY PATHOLOGISTS



Dr. Fraser Hill

BVSc (with distinction), MANZCVSc (Sheep Medicine, Pathology), FANZCVSc (Anatomic Pathology)

Dr. Fraser Hill is recognised as a specialist in veterinary anatomic pathology in Hong Kong, Australia and New Zealand. For the past 23 years he has worked in veterinary diagnostic pathology laboratories, both government and commercial operations. He has experience in diagnosis of disease in many animal species utilising skills in anatomic pathology but also with extensive experience in clinical pathology, serology, molecular testing and microbiology.



Dr. Allan Kessell

BVSc, Mast. Vet. Stud. (Pathology), MANZCVSc (Pathology), Dip ACVP (Anatomic Pathology)


Dr. Allan Kessell is a member of the Australian and New Zealand College of Veterinary Scientists in Pathology, and a Diplomate of the American College of Veterinary Pathology in anatomical pathology. He is a registered specialist in Anatomic Pathology in Australia and Hong Kong. He has been a pathologist for over 20 years. He has broad experience both as a diagnostic and academic pathologist, and his areas of interest are cytology, practical veterinary education, and the holistic integration of anatomical and clinical pathology.

All our pathologists are locally based in our laboratory located on campus in City University of Hong Kong, Kowloon Tong. Our pathologists are more than happy to discuss reports results with you either by email or phone. To touch base with our pathologists, please contact our reception at **3442-4849** or email us at infovdl@cityu.edu.hk.

EASTER HOLIDAY OPENING HOURS



CityU VDL will be open for business on **3rd (Tuesday), 4th (Wednesday), and 6th (Friday) of April**. We will be closed on Good Friday **30th March**, Easter Sunday **1st April**, Easter Monday **2nd April**, and Tomb Sweeping Day **5th April**.



CITYU VDL UPDATES: NEW TESTS

MICROBIOLOGY

We are pleased to announce that our microbiology services are now up and running. Below is a list of what we offer:

- Aerobic Culture
- Anaerobic culture
- Sensitivity testing
- MIC Sensitivity
- Staining: Gram Stain
- Staining: Acid fast
- Urinalysis
- Qualitative Faecal Floatation
- Quantitative Faecal Floatation
- Faecal Smear
- Larval Culture

MOLECULAR DIAGNOSTICS: PCR

We are pleased to announce that PCR testings are now available at CityU VDL. Below is a list of PCR tests we currently offer. More tests will be added in due course.

- Aspergillosis fumigatus
- Babesia canis (spp)
- Babesia canis vogeli
- Babesia gibsoni
- Ehrlichia canis
- Tick Fever Panel
- Bordetella bronchiseptica
- Canine Distemper Virus
- Giardia
- Leptospirosis
- Microsporium canis
- Microsporium gypseum
- Chlamydomphila felis
- Feline Coronavirus
- Feline Calicivirus
- Feline Leukemia Virus
- Feline Herpesvirus
- Feline Immunodeficiency Virus
- Mycoplasma felis
- Microsporium gypseum
- Mycoplasma haemofelis
- Tritrichomonas foetus
- Toxoplasma gondii
- Mycobacterium species (M. tuberculosis, M. africanu, M. canettii, M. bovis, M. microti, M. genavense)
- Mycobacterium avium (M. avium, M. kansasii, M. vanbaalenii)
- Mycobacterium avium subsp. paratuberculosis

LABORATORY TIPS & FAQ

How to ensure you get your histopathology reports back in time?

- Make sure you place your biopsy samples in a **10:1 formalin:specimen ratio** to ensure full penetration of formalin.
- If there is inadequate amounts of formalin in the submitted sample, we may have to place it in the right ratio in our laboratory and allow more time for it to fix before processing.

I've got a large sample, should I cut them into small pieces and place them in a urine pot?

- The answer is NO!
- We encourage you to send us the whole tissue.
- Cutting them into small pieces may result in lost of tissues that may have pathology in it and therefore a diagnosis may not be able to be made.
- If you do not have large enough biopsy pots to put your sample in, we have large biopsy buckets you can purchase from us. For more information on size and pricing, please contact us at infovdl@cityu.edu.hk

How can I ensure good formalin penetration in large samples?

- "Bread loafing" is the way to go.
- This can be done by making multiple slices 1cm apart (do not cut right through to the bottom. Leave the tissue at the bottom intact so the whole piece of tissue is still in one piece and can be "fanned out". This helps the pathologist to identify the relationship between the tissues).
- Formalin does not penetrate greater than 5mm into tissue so the tissue cannot be thicker than 1cm. We have large biopsy buckets you can purchase from us if you do not have anything big to put the tissue in.

I want to know more about your services. Is there someone I can talk to?

- Our Diagnostic Service Coordinator, Dr. Ada Chu, is more than happy to organise an appointment with you at your convenience at your clinic and give you an introduction to our services and answer any questions. Please contact her by email at adachu@cityu.edu.hk or by phone at 3442-6538

CITYU VDL UPDATES: NEW TESTS



GENETICS TESTING

CityU VDL has partnered with Orivet Genetics Pet Care to offer Hong Kong veterinarians DNA testing for dogs and cats. Human studies show a 50-70% increase in compliance when a genetic risk is documented and are more likely to take action. Pet owners are likely also to be more compliant when a heritable risk is identified in their pet. Veterinary hospitals focusing on client-centric approaches, such as personalized medicine, have been shown to demonstrate an increase in visits, customer retention and revenue. Building a new service line around screening and prevention contribute to practice growth and improved customer satisfaction. Owners also love to know their pets are being treated as the unique individuals that they are, rather than just any dog or cat. DNA testing falls into two categories; 1) breed identification and 2) identifying potential disease-causing mutations.

BREED IDENTIFICATION

Physical characteristics of a dog are often shared by many breeds. An owner may have been told they have bought a poodle, but in fact, it may well be a bichon frise. The two breeds may look similar physically, but their genetic make-up is completely different. By identifying a dog's genetic make-up and ancestry, it can help you as a veterinarian to create an effective personalized training, wellness, nutrition, and medical program by identifying traits such as the breed's behaviour, adult weight prediction, and screen for any hereditary diseases relevant to the breed.

IDENTIFYING DISEASE-CAUSING MUTATIONS

Most genetics diseases are caused by a single gene mutation. By identifying these deleterious genes, the veterinarian can implement treatment plans or supportive measures before clinical signs becomes apparent. An example is vitamin B12 (cobalamin) deficiency in border collies, beagles, and giant schnauzers. By identifying the mutated gene causing the disease at an early stage in life, the veterinarian can initiate a bi-monthly cobalamin injection before clinical signs are apparent. Another example is genetically identifying hypertrophic cardiomyopathy (HCM) in a cat before any clinical signs arise. By doing so, the veterinarian may offer routine echocardiography to monitor the heart before any clinical signs of HCM is expressed.

Another benefit of identifying presence of any disease-causing genes is to control any hereditary diseases from entering future generations by screening animals prior to breeding.

For more details of the tests and price, please refer to our Services and Fee Schedule or Genetics Testings booklet or contact us at infovdl@cityu.edu.hk or call our Diagnostic Service Coordinator, Dr. Ada Chu, at 3442-6538.

WHAT IS YOUR DIFFERENTIAL DIAGNOSIS?

by Dr. Allan Kessell

In this section, our pathologist will present to you a case submitted to us at CityU VDL with the relevant clinic history and preliminary tests results provided by the referring clinic. We will then allow you to come up with your own list of differentials. The laboratory results and definitive diagnosis will then be presented to you on a different page where you can then check and see if your differentials are correct. This is a fun way to stimulate some thinking.

CLINICAL HISTORY:

A 10 year old male castrated Rottweiler dog was presented to the veterinarian. He had been inactive over the last week, although his appetite was normal. On physical examination his mucus membranes were pale, and there was moderate pitting oedema noted under the skin of the left hindlimb.

TEST RESULTS:

Abdominal ultrasound revealed a mass within the spleen (other abdominal organs were within normal limits). A complete blood examination and biochemical analysis revealed the following out of

reference range results (all other analytes were within normal ranges) (see table 1).

Haematology	Result	Reference Interval
Haematocrit	16	37 – 55 L/L
Reticulocytes	356	10 - 110
Monocytes	1.60	0.1 – 1.3 x 10 ⁹ /L
Platelets	19	200 – 500 x 10 ⁹ /L
Biochemistry	Result	Reference Interval
Total protein	28	54 – 78 g/L
Albumin	12	24 – 38 g/L
Globulin	16	24 – 42 g/L
Cholesterol	2.2	3.9 – 7.8 mmol/L
Calcium	1.7	1.9 – 2.9 mmol/L

Table 1. In-house CBC and biochemistry results showing abnormal results only.

Five days later the dog returned to the clinic for abdominal surgery to explore the splenic mass revealed by ultrasound. At that time a borderline fever was noted (39.2°C), and at surgery an enlarged spleen containing many pale white masses that varied from 4mm – 5cm was removed (figure 1).

The spleen was submitted in formalin to the CityU VDL for histopathological examination.

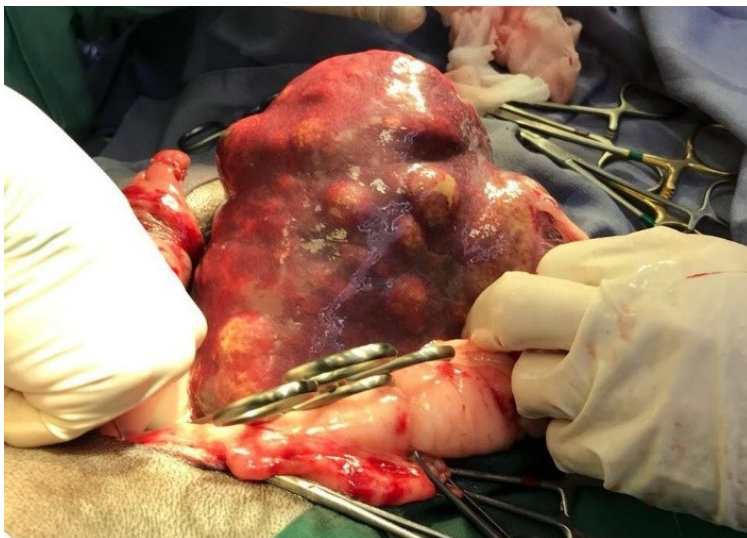

Figure 1. Gross image of pale white masses within the spleen with variable sizes.

The animal's oedema worsened over the following week and became more generalized, but was most severe over the distal extremities and ventral abdomen (figure 2). The dog also developed a snoring type respiration, and multiple CBCs and biochemical panels revealed little change to the abnormalities noted above, even though the dog was transfused on the day of the surgery.

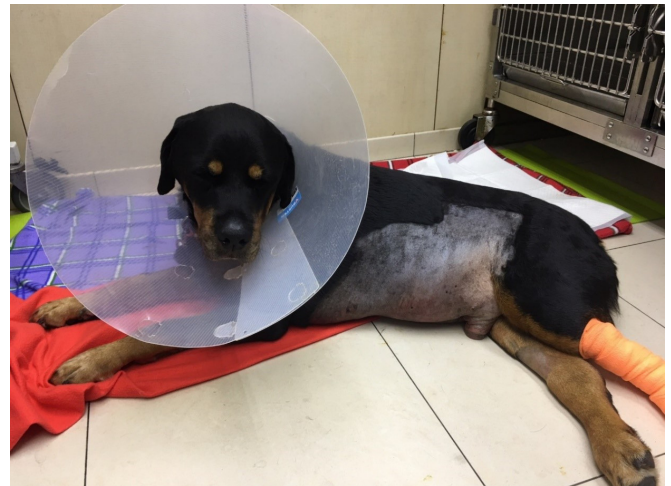

Figure 2. The patient showing generalized oedema. Note the severe preputial and distal limb oedema

Formulate your differential diagnosis that would explain the physical findings and test results, and turn to page 7 histopathology results and general discussion.

CASE OF THE MONTH

by Dr. Fraser Hill

CLINICAL HISTORY:

A five-year-old, domestic longhaired cat was presented for evaluation of mild anorexia and chronic diarrhea. On clinical examination, a large abdominal mass was palpable

and CT scanning confirmed its location in the cranial abdomen. A 70 x 65 x 70 mm firm white mass adjacent to the pancreas surrounded by mesentery was found on exploratory laparotomy. Complete excision was undertaken and the mass sent for histopathological examination. The mass had a necrotic central core. Mesenteric lymph node and duodenal sections to investigate the diarrhea were also collected.

HISTOPATHOLOGY:

Histopathology of the mass found it included a section of normal pancreas adjacent to a neoplastic cell proliferation (Figure 1). In one area, the pancreas and the mass appeared to merge. Here, there was a transformation from normal pancreas to a neoplastic proliferation of ducts with variation in nuclear size and an increased mitotic rate. Many of the individual cells were degenerating and there was extensive necrosis where the tumour cells were outgrowing their blood supply.

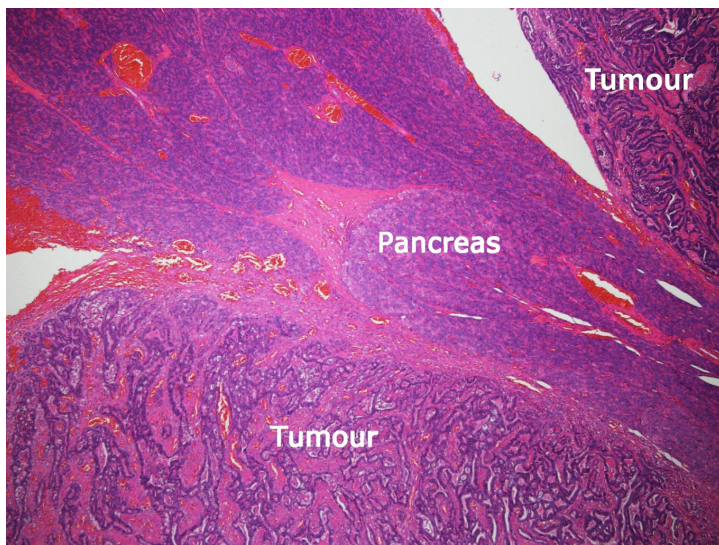


Figure 1. Normal pancreas flanked by proliferations of tumour cells on either side

The nature of the mass was unusual, as the morphology of the cells suggested a ductular carcinoma. The key question was; what was the origin of the mass? Was it from the pancreas or the common bile duct? To investigate this possibility further, a cytokeratin immunohistochemical stain was applied. This stain marks cells of epithelial origin and the image below shows the results (Figure 2). By looking carefully at the interface area between normal pancreas and the tumour it was apparent the tumour cells and the duct cells within the pancreas were the same. This indicated the mass had arisen from the pancreas and a pancreatic duct carcinoma was confirmed. No tumour cells were noted in the lymph node to suggest metastasis had occurred and the samples from the duodenum were normal.

DIAGNOSIS: Pancreatic duct carcinoma

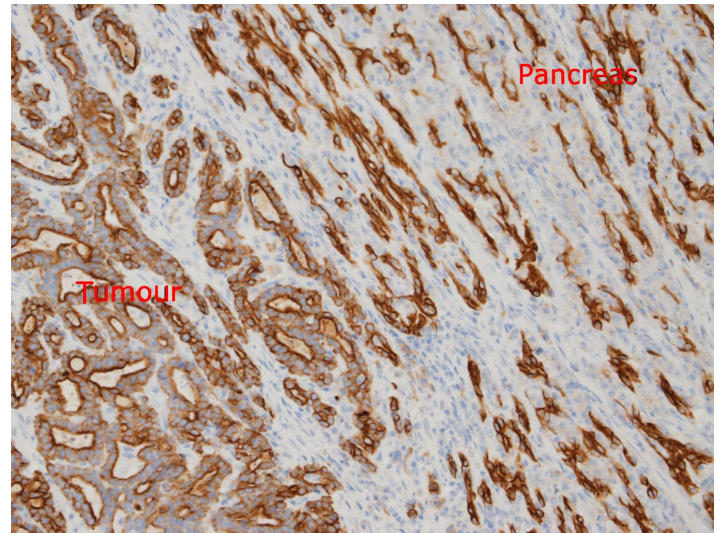


Figure 2: AE1/AE3 stain for cytokeratin indicated the neoplastic cells were of epithelium origin from the pancreatic ducts. At this site, normal pancreatic duct epithelial cells are marked within the pancreas in the upper portion of the image, while neoplastic proliferations of the same cells are visible in the lower portion

DISCUSSION:

The common bile duct of the cat fuses with the pancreatic duct just before entering the duodenal papilla about 30 mm caudal to the pylorus. In some cats the pancreatic duct may open separately but immediately adjacent to the bile duct. Because of the close association of the common bile duct and the pancreas, any pancreatic conditions such as pancreatitis or neoplasia can cause biliary obstruction and icterus.

Following discussions with a veterinary oncologist, it was decided additional therapy for neoplasia was not required at this stage. There was no evidence of tumour metastasis and the cat was progressing well. Treatment for exocrine pancreatic insufficiency and chronic pancreatitis was instituted and the cat's condition will continue to be monitored.



Figure 3. The patient

ACKNOWLEDGEMENTS:

Special thanks to Dr. Sandy Kow from Ivet Animal Clinic for referring this interesting case to us, giving us permission to use this case on our newsletter, and providing us with follow-up information.

WHAT IS YOUR DIFFERENTIAL DIAGNOSIS?

Continuing from page 5

HISTOPATHOLOGY:

The masses within the spleen were dissected out and placed in increased formalin for better fixation. Grossly they appeared well circumscribed, and often bulged from the splenic parenchyma. On section there were variably mottled white and grey.

Microscopic examination revealed that the pale white areas contain sheets of spindle to round cells with many neoplastic features- marked variation in size (anisokaryosis) (figure 3), multinucleation (sometimes 4 nuclei/cell), and a high mitotic rate – 20 mitoses/10 high

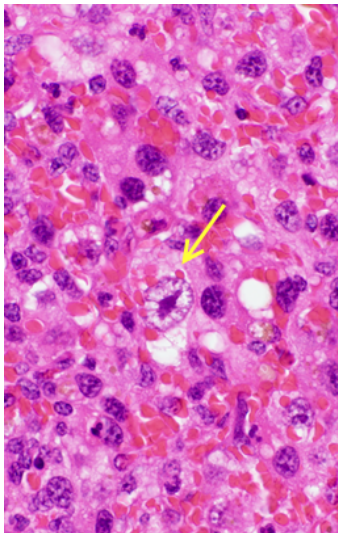


Figure 3. Note large (neoplastic) cell at centre with enlarged nucleolus (yellow arrow).

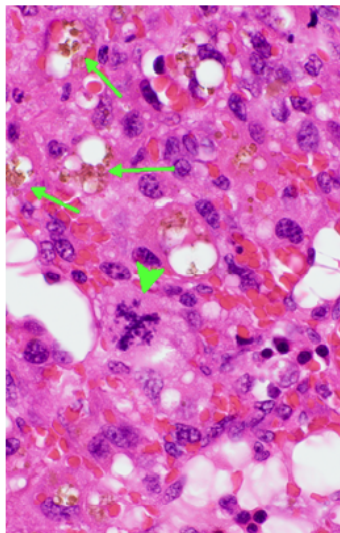


Figure 4. Note abnormal mitoses (arrowhead), some golden brown haemosiderin (arrows).

power fields (HPFs). Some of these neoplastic cells contained a golden brown pigment (haemosiderin) (figure 4), and some had phagocytosed whole RBCs (or occasionally neutrophils). There were scattered areas of necrosis throughout the tumour, and moderate extramedullary haematopoiesis.

The histiocytic nature of this cell line was confirmed with immunohistochemical staining (CD 18, I ba1) (figure 5).

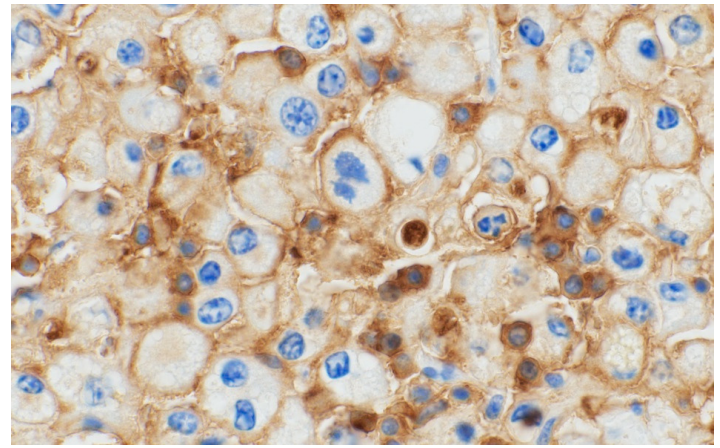


Figure 5. Immunohistochemical staining with CD 18. Membranes of neoplastic cells stained positive (brown)

DIAGNOSIS: Haemophagocytic Histiocytic Sarcoma

DISCUSSION:

The initial clinical pathology results revealed a moderate regenerative anaemia, indicating that the cause was either blood loss or hemolysis (or both), as there was a response from the bone marrow to the anaemia. The finding of panhypoproteinaemia (both albumin and globulins were decreased) suggested that whole blood loss should be strongly considered initially as the cause of the anaemia. There was no history of external blood loss, but blood loss into the abdomen could result in these findings. The fact that we have good regeneration means that the anaemia has been present for at least 5 days and perhaps longer, as first signs of a regenerative response from the bone marrow in the face of a significant anaemia can be seen within 3 days, but takes some time to reach a maximum (if anaemia is due to a single point time cause). If there were blood loss into the abdomen, 80% of the RBCs would be resorbed within 2-3 days, as would most of the protein, so the clinical pathology findings are hard to explain by a single instance of abdominal blood loss. Since we have a splenic mass, the findings may be more consistent with a splenic haemangiosarcoma (HSC) that is haemorrhaging into the abdomen over a period of time, with a recent severe bleed to explain the low PCV. This was the veterinarians number 1 differential, and makes good sense. Usually one can see significant numbers of acanthocytes within the peripheral blood smear in cases of splenic haemangiosarcoma, but that was not examined at the clinic at the time.

Usually you do not see such a low platelet count with just haemorrhage, unless thrombocytopaenia is severe enough to be the cause of the bleeding - the level recorded in this animal is severe enough to result in spontaneous bleeding, and thus causes of severe thrombocytopaenia should also be considered here. In dogs, severe thrombocytopaenia is usually immune mediated, which can be secondary to neoplasia. However, without examination of the peripheral blood smear we cannot rule out that the platelet count is at least partially (and perhaps completely) artifactual and secondary to clumping of platelets within the blood (a very common cause of apparent but artifactual thrombocytopaenia).

The borderline monocytosis may have been secondary to the necrosis within the tumour.

Certainly the albumin is low enough to have resulted in peripheral oedema (hypo-osmotic oedema), and oedema of the soft tissues around the larynx was the likely cause of the snoring respiration.

Once the splenic mass was revealed at surgery, the multifocal nature of the masses and their appearance (and especially colour) does not support a diagnosis of HSC, although would suspect neoplasia. The white colour is more likely due to sheets of tissue cells, perhaps round cells or WBC types since the masses were also not hard on palpation (which would have suggested a spindle cell neoplasm), nor were they fluctuant (which may have suggested abscesses).

And so it proved on histopathology. The neoplastic cells were histiocytes, confirmed with immunohistochemical stains CD18 and Iba1. Histiocytes belong to that group of cells that include antigen presenting cells, and which are also related to macrophages. Most veterinarians are familiar with the very common benign canine skin tumour Cutaneous Histiocytoma. It is usually a single skin mass, and often in dogs <3 years of age (but they can be older). However there are some intermediate tumour forms of histiocytic disease (histiocytoses), and truly malignant forms called Histiocytic Sarcomas. Of these latter forms there is an uncommon type where the neoplastic cell arises within the red pulp splenic macrophages, and that form is termed Haemophagocytic Histiocytic Sarcoma.

Normal splenic red pulp macrophages phagocytose old RBCs (roughly 1% of RBCs/day), but when neoplasia

arises within this cell line it leads to uncontrolled phagocytosis of RBCs within the spleen, and the development of a regenerative anaemia. Thus the condition clinically can resemble immune mediated haemolytic anaemia, but there are no spherocytes in the peripheral blood and these dogs are Coombs negative. The cause of the thrombocytopaenia and hypoalbuminaemia, which is characteristic of this form of histiocytic sarcoma, is not fully explained. Certainly there are areas of necrosis within the tumour seen histologically (which may also explain the fever this animal was showing) that can contribute to thrombocytopaenia. As well one can surmise there may be an immune component. Suggested causes of the low albumin have been a negative acute phase protein effect (down regulation of the livers production of albumin due to cytokine stimulation seen in inflammatory conditions). I do not have an explanation for the low globulins, but if the platelet count is real (and not artifactual), could there have been loss of whole blood through the gastrointestinal tract?

ACKNOWLEDGEMENT

Special thank you to the veterinarian who forwarded this interesting case to us and allowing us to publish it in our newsletter.

CONTACT US

Phone: (852) 3442-4849

(for specimen pickups, consumable purchase, submission forms, specimen bags, and pricelist)

Fax: (852) 3442-0819

Email: infovdl@cityu.edu.hk

Address:

Y1710, Academic Building 1
City University of Hong Kong
83 Tat Chee Avenue
Kowloon, Hong Kong



CITYU VETERINARY DIAGNOSTIC LABORATORY
城大動物醫療檢驗有限公司

If you have any questions about our tests or want us to have a chat with you in person, please contact **Dr. Ada Chu** at 3442-6538 or adachu@cityu.edu.hk